

Radiofrequency Surgery of the Soft Palate for the treatment of snoring and selected cases of mild Obstructive Sleep Apnea (OSA)

Detlef Brehmer, MD, ENT-Practice Goettingen

Since the first description of an Uvulopalatopharyngoplasty by Ikematsu in 1964 [1] numerous variations of surgical procedures of the soft palate for the treatment of primary snoring and OSA have been published. This paper describes our approach with snoring patients and patients with mild OSA ($10 \leq \text{AHI} \leq 20$) performing the Radiofrequency Assisted Soft Palate Procedure (RAPP) first presented by Tvinnereim using a plasma mediated RF-based device [2].

Introduction: Snoring and OSA are different manifestations of the same pathophysiological disorder. Snoring per se is not dangerous to overall health, but can become a social problem for the snorer as well as for the bed partner. Whether snoring can be considered a cardiovascular risk factor or not is controversial [3, 4]. Substantial evidence shows that patients with OSA have an increased risk of cardiovascular disease. Continuous positive airway pressure (CPAP) is the treatment of choice for patients with OSA. However, compliance with CPAP has been less than ideal [5]. After failure of conservative treatment options, more invasive interventions are requested by the snoring patients as well as by patients suffering from OSA.

Patients: The preoperative routine includes anamnestic questions, filling out a questionnaire by the patient (ESS,VAS) and a patient examination including flexible rhinopharyngoscopy. All patients undergo a cardiorespiratory polygraphy with the ApnaeGraph (MRA-Medical Ltd, Gloucestershire,UK). Besides the polygraphic parameters, the ApnaeGraph records the respiratory effort via two pressure sensors on a thin probe (2mm in diameter) which is introduced transnasally. It also records airflow via two temperature sensors. That way, an upper obstruction (uvula and above) can be differentiated from a lower obstruction (below the uvula). The exclusion criteria for RAPP are: $\text{AHI} \geq 20$, $\text{BMI} \geq 30$, tonsil size: ≥ 3 (Friedmann table), modified Mallampati-classification [6] ≥ 2 . If a patient has more than 40% of the obstructions on the lower level, the RAPP should not be performed because there is a high likelihood for failure.



Figure 2: CURIS® radiofrequency unit (Sutter Medizintechnik GmbH)

Methods: With cooperative patients, RAPP is performed under local anaesthesia. Anxious patients or patients with a strong gag reflex should be treated under general anaesthesia. The soft palate is disinfected with a mucosal antiseptic spray and treated with xylocaine gel 2%. After 20 minutes the soft palate is injected at five places in a half-moon shape, and at two spots above the base of the uvula, each time with 1-2 ccm xylocaine 1% with adrenaline 1:200000. The patient rests on the OR table in a half-sitting position, the patient plate is attached. The surgeon stands at the patient's right side. The patient himself depresses the tongue with a 90°-angled tongue depressor. That way, he can regulate pressure on the tongue himself. For the RAPP we use the Sutter Radiofrequency-Unit (Sutter Medizintechnik, Freiburg/Germany) in the „Cut 1“ monopolar mode at an intensity of 3.5 (BM-780 II) or 25 Watts (CURIS®). The uvula is grasped with a forceps at its tip and pulled to the right, tightening the left soft palate. With the monopolar needle electrode (Sutter

ARROWtip™) an incision as described by Tvinnereim [2] is made. The soft palate is cut in an angle of approx. 45° towards the lateral wall through the posterior pillar and into the anterior pillar (Figure 1). The opposite side is treated in the same fashion, resulting in a large transversal opening. If a less pronounced retraction of the tissue is desired, a more horizontal cut is made, as recommended by Tvinnereim [2]. For thick-walled soft palates, an incision line at an angle of 60° to the lateral wall has proven to be advantageous [2]. The lower third of the uvula is resected with a horizontal cut.

The bipolar probe for the soft palate is inserted into the existing incision, as shown in Figure 3. Each time, after placement of the electrode, RF energy is applied for 5 seconds at an intensity of 2.5 (BM-780 II) or 10 Watts (CURIS®) for tissue volume reduction of the soft palate.

Conclusion: The Radiofrequency Assisted Soft Palate Procedure as described is a minimally invasive, safe and quick procedure. It is well tolerated by patients. We have not observed any bleeding that needed special attention. Postoperatively, only minimal swelling occurs. Analgesics are only required occasionally.



Detlef Brehmer, MD
ENT-Practice
Goettingen, Germany

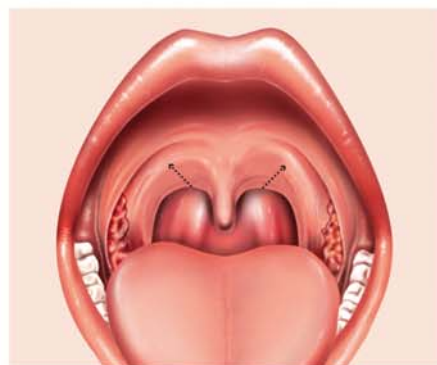


Figure 1: Incision line through the soft palate as described by Tvinnereim

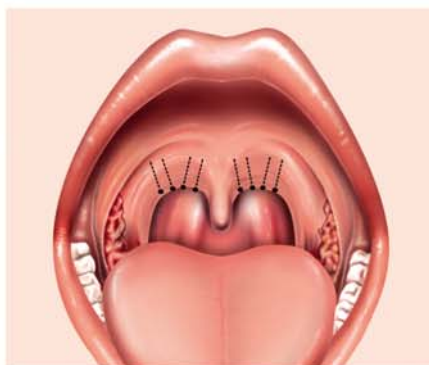


Figure 3: The probe for the soft palate is inserted from below into the existing incision

Correspondence: Priv.-Doz. Dr. med. Detlef Brehmer, ENT-Practice, Friedrichstr. 3/4, 37073 Goettingen, Germany Tel. +49 (551) 49 80 80, Fax +49 (551) 49 80 830, e-mail: d.brehmer@hno-praxis-goettingen.de

References: 1. Ikematsu T (1964) Study of Snoring IV: therapy. *J Jpn Otol Rhin Laryngol* 64: 434 – 35
2. Tvinnereim M, Mitic S, Hansen RK (2007) Plasma radiofrequency preceded by pressure recording enhances success for treating sleep-related breathing disorders. *Laryngoscope* 117:731-6
3. Smirne S, Palazzi S, Zucconi M, Chierchia S, Ferini-Strambi L (1993): Habitual snoring as a risk factor for acute vascular disease. *Eur Respir J* 6: 1357-61
4. Zaninelli A, Fariello R, Boni E, Corda L, Alicandri C, Grassi V (1991) Snoring and risk of cardiovascular disease. *Int J Cardiol* 32: 347-51
5. Shamsuzzaman AS, Gersh BJ, Somers VK (2003) Obstructive sleep apnea: implications for cardiac and vascular disease. *JAMA* 290:1906-14
6. Samsoon GL, Young JR (1987) Difficult tracheal intubation: A retrospective study. *Anaesthesia* 42: 487-90